



PATIENT PRESENTING CLINICAL SIGNS

PATIENT Odin Verigin History: Chronic intermittent vomiting/regurgitation possibly associated with diet change (raw to urinary diet). Minimal improvement with various dietary changes.

SPECIES Feline Physical Examination: Clinically normal.

BREED DSH Urinalysis: Normal.

SEX MN
AGE 9 ½ years
WEIGHT 7.2 kg
CBC: Normal.
Serum Biochemistry: Normal.
Radiographic Findings: N/A.

ULTRASONOGRAPHIC EXAMINATION OF THE ABDOMEN

Urinary System

Full urinary bladder with a normal thickness (0.1 cm) and appearance of the wall. Moderate amount off floating hyperechogenic sediment. No uroliths evident.

Normal trigone area, proximal urethra, and iliac blood vessels.
Normal iliac lymph nodes. Ureters not visualized.

Normal renal size (left 4.3 cm, right 4.4 cm) with increased echogenic appearance, some loss of cortico-medullary differentiation, and normal capsule, blood flow and pelvis.

Reproductive System

Small hypoechogenic prostate (0.4 cm).

Adrenal Glands

Normal shape, echogenic appearance, size, and position. Left 0.9 x 0.44, right 0.92 x 0.38/0.36 cm.

Spleen

Normal size (1.1 cm) and echogenic appearance. Smooth homogenous parenchyma, smooth curvi-linear capsule, and normal vasculature. No evidence of inflammatory, neoplastic, infarction, or infiltrative changes noted.

Liver

Normal size, echogenic appearance, and portal markings. No nodules or massed evident. Small gall bladder containing normal anechoic bile. Normal thickness and echogenic appearance of the gall bladder wall. Normal bile duct.

INTERPRETED BY

Remo Lobetti, BVSc,
MMedVet (Med), PhD,
Dipl. ECVIM

IMAGING PERFORMED BY

Dr Alastair Westcott,
DVM

HOSPITAL NAME

REFERRING VET

Dr Alastair Westcott,
DVM

INVOICE

302804

DATE

3/11/22



PATIENT *Gastrointestinal*

Odin Verigin Normal appearance of the, duodenum, small intestine, ileo-cecal junction, and colon with no loss of layering, normal wall thickness (duodenum 0.24 cm, colon 0.11 cm) and peristaltic activity, and no distension of the lumen. Small mucosal nodule (0.7 cm) in the gastric antrum. Non-shadowing material within the pylorus extending into the proximal duodenum. Fecal material in the colon.

SPECIES

Feline

Pancreas

BREED

DSH

Normal size (right 0.5 cm, left 0.8 cm) and echogenic appearance. Small hypoechogenic parenchymal nodules. Regular capsule. Normal echogenic appearance of the mesentery and fat surrounding the pancreas.

SEX

Free Abdomen

MN

No mesenteric lymphadenomegaly.

AGE

No ascites.

9 ½ years

ULTRASONOGRAPHIC FINDINGS

WEIGHT

7.2 kg

Primary Findings:

- Pyloric/duodenal foreign body?
- Gastric nodule.
- Pancreatic nodules.

INTERPRETED BY

Remo Lobetti, BVSc,
MMedVet (Med), PhD,
Dipl. ECVIM

Secondary Findings:

- Urinary bladder sediment.
- Age-related renal changes.

IMAGING PERFORMED BY

Dr Alastair Westcott,
DVM

INTERPRETATION OF THE FINDINGS & FURTHER RECOMMENDATIONS

Although the most likely etiology for the material in the pylorus/proximal duodenum would be ingesta, a soft material-like foreign body cannot be excluded.

HOSPITAL NAME

Etiologies for the gastric nodule would be granuloma, hyperplasia, and neoplasia.

REFERRING VET

Although the pancreatic nodules may be incidental, neoplasia and granulomas need to be considered.

Dr Alastair Westcott,
DVM

With the presenting clinical signs, inflammatory bowel disease, dietary hypersensitivity, and parasitic enteritis needs to be considered.

INVOICE

302804

Further assessment would be fecal analysis, cobalamin assay, and FNA cytology of the pancreatic nodules and if possible the gastric nodule. Repeating the ultrasound after a 24-hours fast would be recommended and if there is no change in the appearance of the pylorus/proximal duodenum then gastroscopy or laparotomy would be indicated. If a foreign body has been excluded then endoscopy of the upper GI tract with biopsies would be indicated.

DATE

3/11/22



PATIENT

Odin Verigin

Specific therapy would be dependent on an etiological diagnosis. If a foreign body has been excluded then symptomatic therapy would be a course of fenbendazole and/or metronidazole, novel protein/hypoallergenic diet, and possibly prednisolone.

SPECIES

Feline

IMAGES

Stomach

BREED

DSH

SEX

MN

AGE

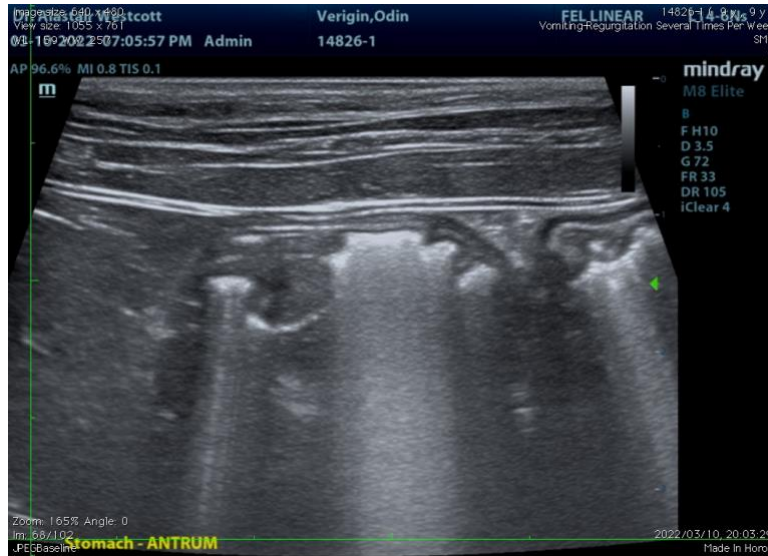
9 ½ years

WEIGHT

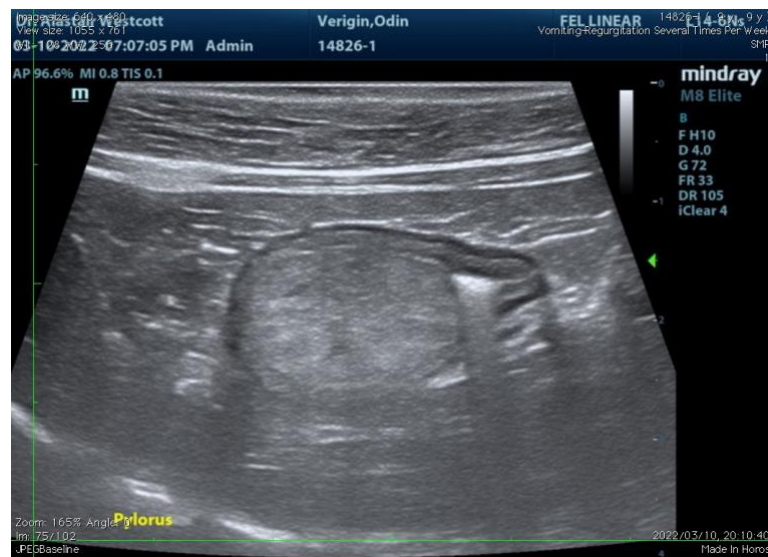7.2 kg

INTERPRETED BY

Remo Lobetti, BVSc,
MMedVet (Med), PhD,
Dipl. ECVIM



Pylorus



IMAGING PERFORMED BY

Dr Alastair Westcott,
DVM

HOSPITAL NAME

REFERRING VET

Dr Alastair Westcott,
DVM

INVOICE

302804

DATE

3/11/22



PATIENT

Duodenum

Odin Verigin

SPECIES

Feline

BREED

DSH

SEX

MN

AGE

9 ½ years

WEIGHT

7.2 kg

INTERPRETED BY

Remo Lobetti, BVSc,
MMedVet (Med), PhD,
Dipl. ECVIM

IMAGING PERFORMED BY

Dr Alastair Westcott,
DVM

HOSPITAL NAME

REFERRING VET

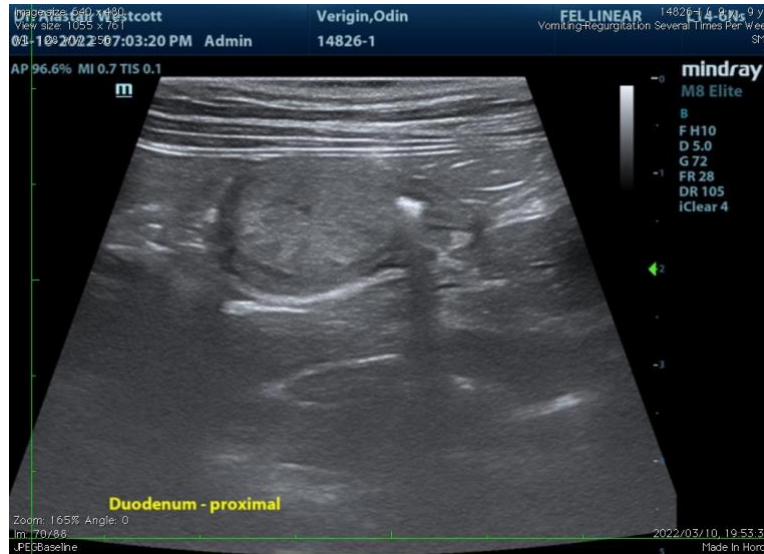
Dr Alastair Westcott,
DVM

INVOICE

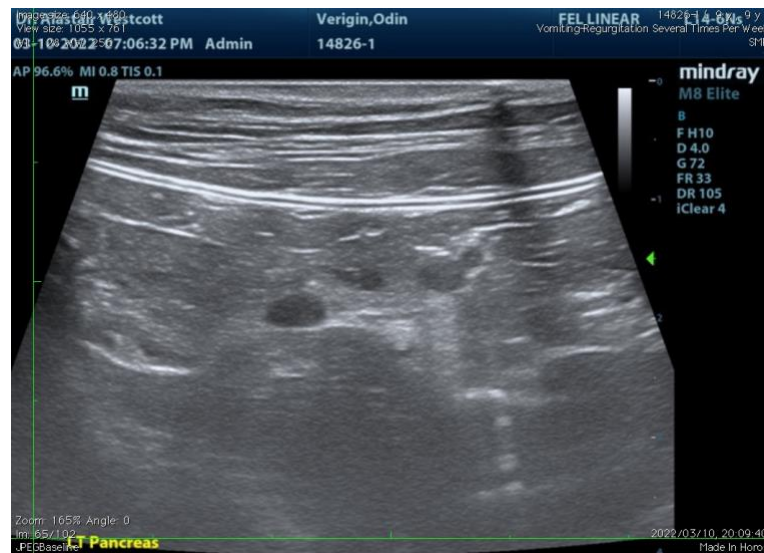302804

DATE

3/11/22



Pancreas



The information and recommendations provided are based on the images presented by the referring veterinarian. No evaluation can be communicated regarding pathology that was not visible in the image/video clips provided.

Thank you for this referral. If the clinical or image interpretation does not parallel your findings or if I can be of any further assistance, please contact me.

Remo Lobetti, BVSc, MMedVet (Med), PhD, Dipl. ECVIM (Internal Medicine)
rlobetti@mweb.co.za